



CLINICAL EVALUATION OF A NEWLY DESIGNED SINGLE-STAGE CRANIOFACIAL IMPLANT: A PILOT STUDY

Mohamed Moataz Khamis, BDS, MS, PhD,^a Ahmed Medra, MD, BDS, MS, PhD,^b and John Gauld^c

Faculty of Dentistry, Alexandria University, Alexandria, Egypt

Statement of problem. Placing craniofacial implants in a 2-stage procedure requires an additional second-stage surgery that is tedious for patients and clinicians and results in additional cost.

Purpose. The purpose of this study was to clinically evaluate the use of a newly designed craniofacial implant for retaining facial prostheses, placed in a single-stage surgical procedure.

Material and methods. Twenty-one newly designed craniofacial implants (OsteoCare Implant System) were placed in 7 patients, all seeking implant-retained auricular prostheses, using a single-stage surgical procedure. Modified O-ring abutments were directly screwed onto the implants at the time of surgery. Plastic washers were attached to the O-ring heads of the exposed abutments to avoid skin overgrowth to allow a single-stage surgical procedure. After a delayed loading period of 4 months, a silicone prosthetic ear was fabricated and retained using clips over the O-ring abutments. Implants and surrounding tissues were clinically evaluated at 1, 6, and 12 months following prosthesis insertion. The following were evaluated: periimplant abutment sebaceous crusting, periimplant abutment exudate, skin thickness, periimplant abutment tissue reaction, and implant mobility. Data was collected and statistically analyzed using the nonparametric Friedman's test for overall comparisons and Wilcoxon signed rank test for post hoc assessment of significance between follow-up periods.

Results. None of the implants failed to osseointegrate, providing a survival rate of 100%. Periimplant abutment sebaceous crusting values were significantly reduced at the 12-month test session ($P < .05$). Periimplant abutment skin thickness was also significantly reduced ($P < .05$) between the 6- and 12-month, and 1- and 12-month, follow-up visits. No significant difference was found throughout the follow-up period for periimplant abutment exudates and tissue reactions. None of the implants showed any signs of mobility throughout the study period.

Conclusions. The use of the single-stage surgical procedure, together with the newly designed craniofacial implants, provided a high survival rate for an evaluation period of up to 2.5 years in the present investigation. (J Prosthet Dent 2008;100:375-383)

CLINICAL IMPLICATIONS

This pilot study indicates that placing craniofacial implants to support auricular prostheses using a single-stage surgical procedure overcomes the problems associated with a 2-stage procedure and is, therefore, more convenient for both patients and clinicians.

The use of osseointegrated implants to retain facial prostheses has become an integral part of treatment planning for facial reconstruction. Implant retention is currently considered the standard of care in many situations because of the numerous

advantages it provides over adhesive retention.¹⁻⁵ Protocols for the fabrication of craniofacial implant-retained prostheses have been evaluated and documented in several studies.^{1,2,6,7} However, their use has been associated with several limitations, including

the limited thickness of facial bones, variation in periimplant soft tissue thickness, difference in bone quality between various facial sites, need for 2 surgeries, time required before loading, and the difficulty in locating implants at stage-2 surgery.

^aProfessor, Prosthodontic Department.

^bProfessor, Maxillofacial Surgery Department.

^cDirector, AMB Engineering, Ltd, Berkshire, UK; Consultant Engineer for OsteoCare Implant System, Ltd, Berkshire, UK.



Since the introduction of craniofacial implant-retained prostheses in 1977,⁸ few implants specifically designed for extraoral use have been introduced. The most popular was the Brånemark craniofacial implant (Nobel Biocare AB, Göteborg, Sweden), which has been evaluated in many studies.^{2,4,6,8,9-15} Other implant designs, such as the 3.5-mm endosseous screw-type implant (Bud System, East Aurora, NY), have also been used, and high levels of survival were reported.^{7,16} Attempts at using short intraoral implants have been reported in a few studies.^{17,18} Six-mm-long implants (Institut Straumann AG, Basel, Switzerland) and 5-mm-long implants (IMTEC Corp, Ardmore, Okla) have been used, with levels of survival similar to the craniofacial implants.^{17,18}

Many implant systems are currently available for intraoral use, with different strategies and designs to match and overcome difficult oral conditions, improving the prosthetic outcome. However, craniofacial implants have not gained much attention, largely due to the small population of patients in need of extraoral rehabilitation and the few systems available.^{19,20} Most of the studies reported using the 2-stage surgical procedure for placing craniofacial implants, to allow for undisturbed healing.^{4,8,9,11,12,14,21} Different attachment mechanisms have also been proposed and evaluated in various studies.^{1,3,9,22-25} Splinting implants with a bar-type attachment has been popular, in spite of its limitations, which include technical difficulty and time required for bar fabrication, difficulty in cleaning under the bar, and increased cost.^{3,4,8,12,18,26,27} The high level of survival of craniofacial implants reported in several studies,^{2,4,6,8,9-18} together with improved patient acceptance and satisfaction, encourages their development and improvement. In the present investigation, a newly designed single-stage craniofacial implant was clinically evaluated for retaining facial prostheses. It was hypothesized that the single-stage

technique would jeopardize the survival rate of the implants evaluated.

MATERIAL AND METHODS


A new implant (OsteoCare Implant System, Ltd, Berkshire, UK) specially designed by the author for craniofacial use was evaluated in this study, which received institutional review board approval from the Ethics Committee of the Faculty of Dentistry, Alexandria University, Alexandria, Egypt. The titanium implant is provided in 2 lengths, 4 mm and 5 mm. It has a standard diameter of 5 mm, a 1-mm smooth collar, a reverse buttress thread, a flat platform, and an internal hex abutment interface. Specially designed O-ring abutments (OsteoCare Implant System, Ltd) of varying lengths are provided with the system to accommodate different skin thicknesses. The abutment shaft is tapered to a small O-ring that provides for easier cleaning and improved periabutment hygiene (Fig. 1).

Seven patients (age range, 7-32 years, with a mean age of 20 years) presenting with missing auricles were enrolled in the present study, agreed to participate in this investigation, provided informed consent, and then had a total of 21 implants placed among them. Included in the study were patients who had congenitally missing ears or who had lost their ears due to accidents. Patients also had to have at least 5 or 6 mm of bone thickness in the mastoid area

to allow for implant placement. A computerized tomography scan (CT scan) was performed for each patient to evaluate the amount of available bone. Patients who had lost their ears because of tumors or who had been exposed to radiation treatment were excluded. Patient characteristics are presented in Table I. A clear acrylic resin (Orthocryl 2000; Dentaureum, Inspringen, Germany) surgical template was fabricated to aid in proper implant positioning in the mastoid area. Three implants were placed for each patient, positioned in a tripod configuration (Fig. 2).

Implants were placed using standard surgical procedures.¹² A special surgical kit (OsteoCare Implant System, Ltd) corresponding to the specific length and diameter of the modified craniofacial implants was used. The kit included 3 drills of increasing diameter, the final drill corresponding to the implant diameter. The kit also contained an implant driver and a ratchet wrench. Subsequent to a proper drilling sequence and osteotomy preparation, implants were initially placed by hand, until finger pressure was insufficient to screw the implants completely into place. They were then finally seated using the ratchet wrench (OsteoCare Implant System, Ltd), which indicated that they were strongly anchored in the bone and, thus, initially stable.

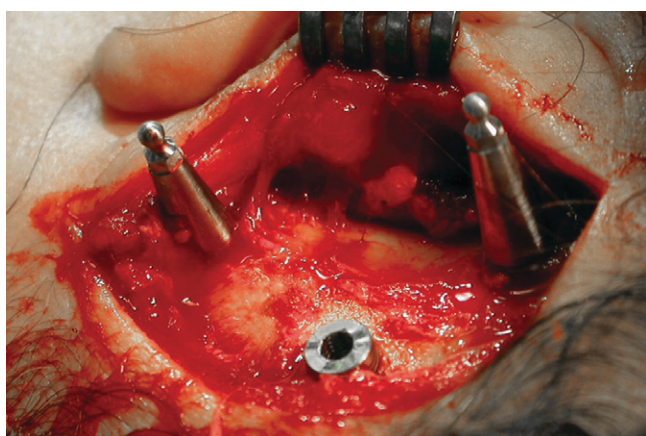
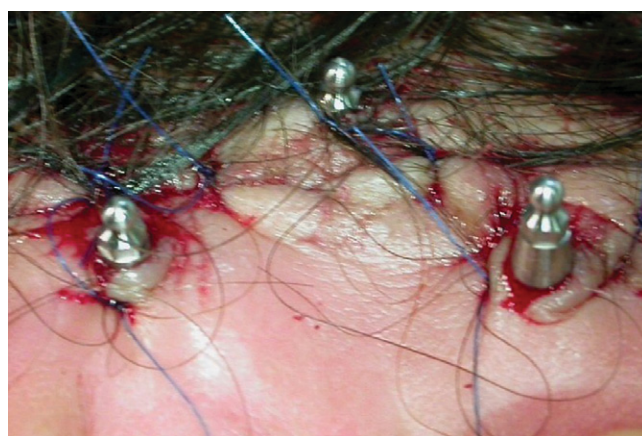After the implants were placed, the O-ring abutments were directly screwed onto the implants by hand.



1 Implant and O-ring abutment.

TABLE I. Patient characteristics. Three implants were placed in all patients; all implants survived

Patient Number	Age (Years)	Gender	Cause of Defect	Implant Length (mm)	Time Integrated (Months)
1	32	female	congenital	5	20
2	31	male	congenital	5	12
3	31	male	congenital	4	12
4	17	female	trauma	5	30
5	7	female	congenital	4	15
6	8	female	congenital	4	13
7	13	female	trauma	5	21

**2** Implants placed in tripod configuration.**3** Abutments exposed after suturing of flap.

Abutment lengths were selected so that at least 2 mm of abutment body below the O-ring head was exposed over the skin after flap closure to ensure a single-stage procedure (Fig. 3). Abutments were tightened at this stage only by hand to allow for the possibility of changing abutment length after complete soft tissue healing. For most of the patients, the incision for the original mucoperiosteal flap was made approximately 1 cm distal to the proposed implant site placement. The flap was therefore perforated, allowing the abutment heads to penetrate through the sutured flap. The raised flap was not routinely undermined, nor was a split thickness skin graft used for any of the patients.

To avoid surgical edema, swelling, and skin overgrowth that could completely cover the exposed abutments, specially designed plastic washers (Os-

teoCare Implant System, Ltd) were attached to the O-ring abutments. The plastic washers were round, button shaped, and 1 cm in diameter, with a central plastic clip to retain them to the O-ring abutments (Fig. 4). The retaining clip was later removed and indexed to the internal aspect of the auricular prosthesis for the purpose of retaining it to the abutments, and the washer was discarded. The plastic clip provided the washer with adequate retention to avoid dislodgement. The washer permitted good seating of the tissues around the abutment and onto the underlying periosteum. Auricular remnants or tissue tags in patients with microtia (congenitally deformed ears) were surgically removed to create a more suitable base, onto which the prostheses were more favorably fabricated.

Implants were left unloaded for

an average of 4 months to facilitate osseointegration. Patients were instructed not to exert excessive forces on the exposed abutment heads and avoid trauma. After soft tissue healing and suture removal (about 10-14 days following surgery), patients were instructed to lightly clean the abutments and periimplant tissues using a gauze saturated with povidone-iodine USP 4.00% w/v (Betadine solution; Mundipharma AG, Basel, Switzerland). After complete soft tissue healing (about 4 weeks), patients were instructed to clean the abutments using regular soap and water once daily.

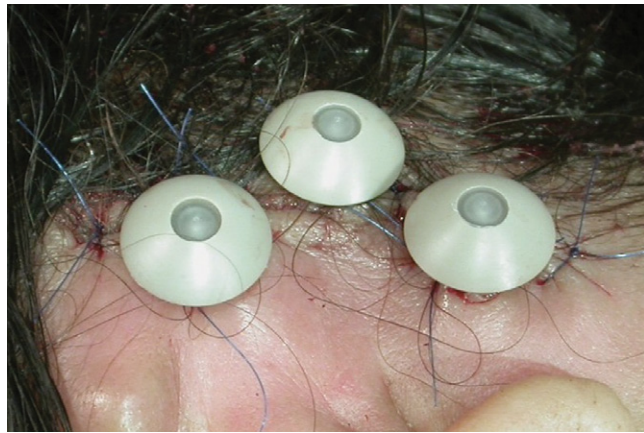
After 4 months, implants were evaluated for osseointegration (Fig. 5). The criteria for determining successful osseointegration included absence of clinically detectable implant mobility and absence of spontaneous pain or pain during abutment

tightening. Abutments were tightened to 35 Ncm using a torque wrench (OsteoCare Implant System, Ltd) to avoid their subsequent loosening and ensure that implants were firmly anchored in bone without pain. Mobility was examined using the ends of 2 hand instruments. In some patients, abutments were found to be too long and thereby interfering with the external contour of the definitive prosthesis. The abutments were replaced with shorter ones. Retaining clips were placed onto the abutments, and a definitive impression was made using a vinyl polysiloxane material (Reprosil; Dentsply Caulk, Milford, Del). A type IV stone cast (Fujirock EP; GC Europe, Leuven, Belgium) was prepared, onto which a clear acrylic resin backing was fabricated to maintain the retaining clips. The acrylic resin backing area was outlined on the stone cast and fabricated using autopolymerizing acrylic resin (Orthocryl 2000; Dentaaurum). A wax sculpture of the missing ear was made to match the opposite ear in size and shape. It was then attached to the acrylic resin backing, evaluated on the patient's face, and adjusted as necessary. A 3-piece mold of the wax ear was then made using dental stone. The wax was then eliminated by immersion in a hot water bath, and the mold was cleaned and dried. The clear acrylic resin backing was repolished from both sides and properly positioned in place on the stone cast. To ensure effective bonding between the acrylic resin backing and silicone, the acrylic resin backing was cleaned using gauze saturated with acetone, primed (Primer S-2260; Dow Corning Corp, Midland, Mich), and left for 1 hour. A thin layer of medical adhesive type A silicone (Silastic Medical Adhesive Silicone, Type A; Dow Corning Corp) was placed onto the acrylic resin backing, and then the mold was further packed with skin color-tinted medical grade silicone (Silastic MDX4-4210; Dow Corning Corp). The definitive silicone prosthesis was finished and custom tinted to closely match the patient's

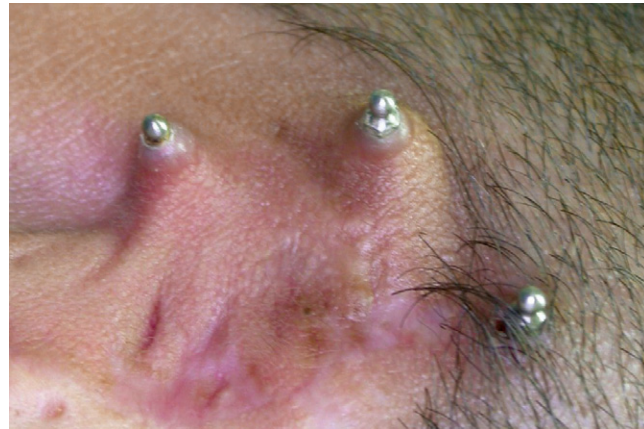skin color (Fig. 6). Retaining clips were placed onto the implants and their position properly relieved in the acrylic resin backing. They were then picked up using clear autopolymerizing acrylic resin (Acry Self; Ruthinium Dental Products, Ltd, Badia Polesine, Italy). Excess material was removed, and the acrylic resin backing was finished and polished.

Implants and surrounding tis-

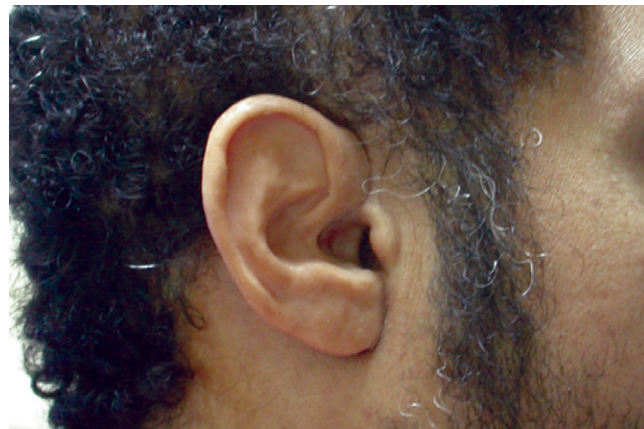suces were evaluated after 1, 6, and 12 months of prosthesis insertion. The following were evaluated: periimplant abutment sebaceous crusting, periimplant abutment exudate, skin thickness, periimplant abutment tissue reaction, and implant mobility. Patients in the current study were followed from 12 to 30 months after implant placement. The sebaceous material adherent to the implant abut-



4 Plastic washers attached to abutments after flap closure.



5 Implants osseointegrated after 4 months of healing. Note healthy periimplant abutment skin.



6 Definitive silicone auricular prosthesis.

ments was visually quantified prior to all other measurements. This provided an evaluation of patient hygiene. Four grades were used, according to the criteria proposed by Gitto et al⁷: grade 0 represented no crusting; for grade 1, a small amount of crusting was evident but not encircling the entire abutment; for grade 2, a moderate amount of crusting not encircling the entire abutment was present; and grade 3 represented heavy accumulation of crusting encircling the entire abutment. The presence of periimplant abutment exudate was visually observed and recorded.⁷ Grade 0 indicated no exudate, grade 1 indicated serous exudate, while grade 2 denoted purulent exudate.

Skin thickness was measured using a plastic periodontal probe inserted along the long axis of the implant abutment until resistance was met. To standardize the probing pressure each time the test was conducted, a pressure-sensitive plastic periodontal probe (PDT Sensor Probe; Pro-Dentec, Batesville, Ark) was used. Probing was performed at 4 sites around each abutment.

Periimplant abutment tissue inflammation was visually assessed.⁷ Grade 0 denoted normal skin, grade 1 indicated mild inflammation (slight redness and/or edema, nontender), grade 2 indicated moderate inflammation (redness, edema, mild tenderness), while grade 3 included severe inflammation (marked redness, edema, ulceration, moderate to severe pain).

Mobility was tested by applying alternative back and forth pressure by the back of 2 hand instruments on the sides of the implant abutment. Clinical mobility was graded as 0, for no mobility, and grade 1 for clinically detected mobility. Implant survival was followed for a minimum of 1 year and a maximum of 2.5 years. Data were collected and statistically analyzed using the nonparametric Friedman's test for overall comparisons and Wilcoxon signed rank test for post hoc assessment of significance between follow-up periods ($\alpha=.05$).

RESULTS

Throughout the study period, none of the implants failed to osseointegrate, providing a survival rate of 100%. All implants are in function, with the longest longitudinal follow-up being 2.5 years (average 21 months). During the follow-up visits, loosening of abutments was noticed in 28.6% of the patients (2 of 7). Abutments were retightened lightly by hand to avoid exerting excessive pressure, so as not to damage the 1-stage implants. At the first month recall, 42.9% of patients (3 of 7) had a small amount of crusting judged as grade 1, while another 42.9% of patients (3 of 7) had more crusting (grade 2). At the same time, 14.3% of patients (1 of 7) had heavy accumulation of crusting encircling the entire abutment (grade 3). At the 6-month recall, 57.1% of patients (4 of 7) presented with grade 1 crusting, while 42.9% of patients (3 of 7) had crusting judged as grade 2. After 1 year, 85.7% of patients (6 of 7) had grade 1, while the other 14.3% (1 of 7) had grade 2 crusting (Table II). No significant improvement in overall grades was found between the 1- and 6-month recalls and between the 6- and 12-month recall sessions ($\chi^2=4.8$,

$P>.05$). However, a significant ($P=.04$) improvement in grades was found between the 1- and 12-month recalls.

Regarding periimplant abutment exudate at the 1-month recall, 71.4% of patients (5 of 7) had no evidence of periimplant abutment exudate, while 28.6% of patients (2 of 7) had slight serous exudate. At the 6- and 12-month recalls, none of the patients had any periimplant abutment exudate (Table III). No statistically significant difference in overall grades was found between the 1-, 6-, and 12-month recalls ($\chi^2=4.0$; $P>.05$).

Skin thickness (probing depth) after 1 month of implant placement averaged 6 mm. At the 6-month recall, skin thickness was slightly reduced to an average of 5.4 mm, while the mean thickness at the 1-year recall was further reduced to an average of 4.9 mm (Table IV). An overall significant difference was found between the 3 follow-up periods ($\chi^2=8.6$; $P<.04$). No statistically significant difference was found between the mean skin thickness values at the 1- and 6-month sessions. However, a significant reduction in skin thickness was found between the 1- and 12-month ($P=.03$) and 6- and 12-month ($P=.04$) test sessions.

Periimplant abutment tissue re-

TABLE II. Results of periimplant abutment sebaceous crusting grades between test sessions (grade 0: no crusting; grade 1: small amount of crusting not encircling entire abutment; grade 2: moderate amount of crusting not encircling entire abutment; grade 3: heavy accumulation of crusting encircling entire abutment)

Patient	1 Month	6 Months	12 Months
1	3	2	2
2	1	1	1
3	2	1	1
4	1	2	1
5	1	1	1
6	2	2	1
7	2	1	1

Friedman's test ($\chi^2=4.8$, $P>.05$)

TABLE III. Results of periimplant abutment exudate grades between test sessions (grade 0: no exudate; grade 1: serous exudate; grade 2: purulent exudate)

Patient	1 Month	6 Months	12 Months
1	1	0	0
2	0	0	0
3	0	0	0
4	0	0	0
5	0	0	0
6	1	0	0
7	0	0	0

Friedman's test ($\chi^2=4.0$, $P>.05$)

TABLE IV. Results of skin thickness values (mm) between test sessions

Patient	1 Month	6 Months	12 Months
1	6	6	5
2	5	4	4
3	5	5	4
4	6	6	6
5	7	5	4
6	9	8	7
7	4	4	4
Mean (SD)	6.0 (1.633)	5.4 (1.397)	4.9 (1.215)
Median	6.00	5.00	4.00
Z ₁ (P ₁)		1.134 (0.257)	2.060* (.039)
Z ₂ (P ₂)			2.000* (.046)

Friedman's test ($\chi^2=8.6$, $P<.05$)

*Statistically significant difference at $P<.05$

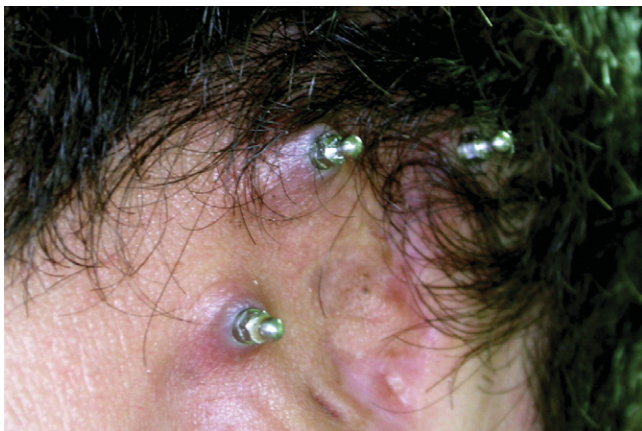Z₁ Wilcoxon signed rank test between 1-month and 12-month follow-up

Z₂ Wilcoxon signed rank test between 6-month and 12-month follow-up

action was evaluated after 1 month of implant placement. No periimplant abutment tissue reaction was found in 28.6% of the patients (2 of 7), while 57.1% of the patients (4 of 7) experienced mild inflammation, evidenced by slight redness (Fig. 7). The remaining 14.3% of the patients (1 of 7) presented with moderate inflammation, evidenced by periim-

plant tissue redness and edema. At the 6-month recall, 71.4% of patients (5 of 7) showed no clinically detectable periimplant abutment tissue reaction, while 28.6% of patients (2 of 7) showed grade 1 tissue reaction. For the 12-month recall, 85.7% of patients (6 of 7) showed no clinically detectable periimplant abutment tissue reaction, while 14.3% of patients

(1 of 7) showed grade 1 tissue reaction (Table V). No significant difference in overall grades for periimplant abutment tissue reaction was found between the 1-, 6-, and 12-month recalls ($\chi^2=3.7$; $P>.05$). Regarding mobility, none of the implants showed any clinical signs of mobility throughout the study period.



7 Mild periimplant abutment tissue reaction (2 months after prosthesis insertion), evidenced by slight redness, slight edema, but no tenderness.

TABLE V. Results of periimplant abutment tissue reaction grades between test sessions

Patient	1 Month	6 Months	12 Months
1	1	0	0
2	0	0	1
3	1	0	0
4	0	1	0
5	1	0	0
6	2	0	0
7	1	1	0

Friedman's test ($\chi^2=3.7, P>.05$)

DISCUSSION

Although the concept of osseointegration is the same whether implants are placed intraorally or extraorally, craniofacial implants should have modified design features to match the anatomical and biomechanical differences in the facial area. In spite of having limited thickness, facial bones are dense. The load and frequency of loading forces on craniofacial implants are limited when compared to implants placed intraorally.

The data in the current pilot study showed that the single-stage technique did not significantly jeopardize the survival rate of craniofacial implants; thus, the hypothesis that the single-stage technique jeopardizes the survival rate of those implants is not supported. Implants in the cur-

rent study were designed for extraoral use. The authors hypothesize that since the implants were 5 mm in diameter without a flange, they provided a large surface area together with lateral stability for better osseointegration. Short implants with lengths of 4 mm or 5 mm were used to suit the limited thickness of facial bones. However, the short length was compensated for by the wide diameter. Moreover, in a previous study, 5-mm-diameter implants, 5 mm and 6 mm in length, were used successfully in the posterior mandible and maxilla where occlusal forces are much greater than those applied extraorally.²⁸ Schlegel et al²⁰ also reported using craniofacial implants (Ankylos; Dentsply Tulsa Dental Specialties, Tulsa, Okla), 3.5 mm in diameter and 4, 5, and 6 mm in length, with a high survival rate.

Implants were designed to have an internal connection to facilitate and simplify initial abutment screw positioning into the implant body. Special drills of increasing diameter, provided with positive stops, were used to prevent penetration of the internal cortex and dura. Abutments tapered to an O-ring head were used. Although several studies used bar and clip retention for its desirable splinting effect and equitable load distribution,^{1,3,6,8,21,26} newly designed O-ring abutments provide good retention, are easier for patients to maintain, are less costly, and simplify prostheses fabrication when compared to bar and clip retention.^{3,25,26} Also, when O-rings are used, as opposed to bars, less metal is visible when the prosthetic ear is removed, which is probably more esthetically satisfying to patients.

In the present study, 3 implants were placed for each patient in an offset, tripod configuration. Although 2 implants might be enough to support and retain a bar-retained auricular prosthesis, a third implant is necessary with O-ring attachments to allow for relief under the artificial ear and, at the same time, avoid rotation of the prosthesis over the round ball head of the attachment.

Most of the studies reporting on the use of craniofacial implants performed a 2-stage surgical procedure with a 3- to 4-month submerged healing period.^{6,14,16,20,21} In the current study, the single-stage surgical procedure was used, and the O-ring portion of the abutment remained exposed through the skin at the time of implant placement. Thus, the second-stage surgery was eliminated, thereby obviating the need for general anesthesia, flap raising, and bone exposure to locate the implants, generally required in the auricular area, in particular, where skin is usually thick. The single-stage technique significantly simplified the procedure both for the patient and clinician.

To avoid the problem of skin overgrowth covering the exposed part of the O-ring abutment, plastic washers



were attached to the abutments using clips. The washers also protected the periimplant skin from irritation and trauma during healing. The retaining clips were later removed from the washers and reused to retain the silicone definitive prosthesis. Although screw-retained plastic washers were used in a previous study,¹⁶ clip-retained washers were used in the current study because the abutments were of the O-ring type. Asher et al²⁹ recommended using a night guard over implant abutments to prevent noises, which could occur from the rubbing of implants against bed linens, from irritating some patients. Plastic washers may also minimize the rubbing effect, improving patient satisfaction.

All 21 implants in the present study osseointegrated, and none showed signs of failure, evidenced by the lack of clinically detectable mobility or pain, throughout the study period. This finding is in agreement with Nishimura et al,²¹ Khamis,¹⁸ and Schlegel et al,²⁰ who reported a survival rate of 100% for craniofacial implants placed in the mastoid area, and further indicates the high predictability in the success rate of craniofacial implants, as documented by many studies.^{4,6,12,13,27} Patients in the current study had not been irradiated, which was a specific exclusion criterion for this investigation. Presumably, a 1-stage craniofacial implant placement approach would not be recommended at this time for those in need of auricular replacement after losing an auricle due to malignancy that was managed with radiotherapy.

Implant survival and periimplant tissue health were evaluated clinically, as this was determined to be the most feasible method for extraoral implant evaluation. Unlike for intraoral implants, periodic radiographic monitoring of craniofacial implants was found to be impractical.^{7,10}

All patients demonstrated sebaceous crusting to varying degrees throughout the study. At the 1-month recall, most of the patients had grade

1 and 2 sebaceous crusting, while only 1 patient had grade 3. This might be attributed to the delicacy which the patients were required to use in managing the implants during the osseointegration period, which may have interfered with optimal hygiene. There was no significant decrease in the amount of sebaceous crusting by time (between the 1- and 6-month, and 6- and 12-month recalls), although the values seemed to decrease after 6 months and then after 1 year. The decrease in crusting may be due to the continuous efforts to emphasize to the patients the importance of hygiene and its effect on implant health, together with the patients' increasing familiarity with and improvement in hygiene measures. This was evidenced by the significant improvement in sebaceous crusting grades between the 1- and 12-month recall. However, all patients had crusting in variable amounts throughout the study. This may be explained by the difficulty in auricular implant hygiene, attributed by Thomas²⁵ to the patients' limited field of vision. It can also be attributed to patients' personal hygiene habits.

Little evidence of periimplant abutment exudate was recorded at the first-month recall, when soft tissue healing was still in progress. The presence of periimplant abutment exudate, which is a sign of infection, might also be related to the amount of sebaceous crusting and frequency of hygiene. Skin thickness was monitored throughout the study period. No significant change was found between the 1- and 6-month recalls. Skin thickness was, however, reduced significantly between the 6- and 12-month recalls, and consequently, between the 1- and 12-month recalls. This again might be attributed to the progressive periimplant soft tissue healing. Although the periimplant skin was thick and hairy in some patients, it did not seem to interfere with implant success.

The periimplant abutment tissue reaction, evidenced by changes in color, edema, and pain, was mild in

the 1-month recall, probably because the periimplant tissues were still in the healing phase and proper hygiene was not feasible. Improvements throughout the follow-up sessions were evident, although not statistically significant. Again, this may be due to the complete healing of the periimplant tissues together with proper hygiene measures that were continuously reinforced. The mild periimplant tissue reaction might also be partially attributed to the presence of thick, hairy skin around implants in some patients interfering with proper hygiene. None of the patients, however, presented with severe inflammation (grade 3) throughout the study period. The results seem to be in agreement with those of Tjellström,²⁰ who reported that 60% of patients had no adverse reactions around any implants.

Slight inflammation, presenting as skin redness, was noted when sebaceous crusting was removed from around implant abutments. The slight inflammation can be explained when comparing sebaceous crusting to calculus around intraoral implant abutments, which acts as a constant irritant and results in inflammation that may ultimately lead to periimplant abutment dermatitis.⁷ It is therefore accepted that good patient hygiene compliance combined with thin, immobile soft periimplant tissue minimizes complications.^{21,26,27} However, none of the patients was able to maintain the level of hygiene required to prevent the occasional development of soft tissue inflammation around the abutments, which is in agreement with the findings of Nishimura et al.²¹ The hygiene of patients was inconsistent, and, therefore, repeated hygiene instructions were necessary. Periimplant tissue reaction in the present study did not compromise osseointegration; this was evidenced by the lack of clinical implant mobility throughout the 1-year recall. This, again, was noted in previous studies.^{11,12,26}

In spite of the small number of patients/implants, relatively short follow-up, and limited implant site skin

preparation, the results of the current study suggest that craniofacial implants placed in a single-stage procedure are predictable. This is probably because patients were instructed not to subject the implants to excessive forces during osseointegration, together with proper initial primary implant stability. Primary implant stability can be predictably achieved in the mastoid bone because of its compact nature. Placing the implants in the prepared osteotomy sites was not possible by hand force. The ratchet wrench (OsteoCare Implant System, Ltd) was always needed to place and tighten the implants. If primary implant stability is not optimal because of reduced bone quality, a short, 1-mm, collar-length abutment with an O-ring head can be placed using a 2-stage technique as a treatment alternative. The short abutment, however, can still be palpated and easily detected at second-stage surgery, minimizing the need for extensive flap elevation. The abutment can later be changed to a longer one of appropriate length for prosthesis attachment.

CONCLUSIONS

Within the limitations of this study, the use of the single-stage surgical procedure together with the newly designed craniofacial implants provided a 100% implant survival rate.

REFERENCES

- Rubenstein JE. Attachments used for implant-supported facial prostheses: a survey of United States, Canadian, and Swedish centers. *J Prosthet Dent* 1995;73:262-6.
- Wolfaardt JF, Wilkes GH, Parel SM, Tjellström A. Craniofacial osseointegration: the Canadian experience. *Int J Oral Maxillofac Implants* 1993;8:197-204.
- Del Valle V, Faulkner G, Wolfaardt J, Rangert B, Tan HK. Mechanical evaluation of craniofacial osseointegration retention systems. *Int J Oral Maxillofac Implants* 1995;10:491-8.
- Lundgren S, Moy PK, Beumer J 3rd, Lewis S. Surgical considerations for endosseous implant in the craniofacial region: a 3-year report. *Int J Oral Maxillofac Surg* 1993;22:272-7.
- Yontchev E. Cranial and maxillofacial epithesis treatment on osseointegrated implants: concept and principles. *J Prosthet Dent* 1985;53:552-3.
- Roumanas E, Nishimura R, Beumer J III, Moy P, Weinlander M, Lorant J. Craniofacial defects and osseointegrated implants: six-year follow-up report on the success rates of craniofacial implants at UCLA. *Int J Oral Maxillofac Implants* 1994;9:579-85.
- Gitto CA, Plata WG, Schaaf NG. Evaluation of the peri-implant epithelial tissue of percutaneous implant abutments supporting maxillofacial prostheses. *Int J Oral Maxillofac Implants* 1994;9:197-206.
- Parel SM, Brånemark P-I, Tjellström A, Gion G. Osseointegration in maxillofacial prosthetics. Part II: Extraoral applications. *J Prosthet Dent* 1986;55:600-6.
- Seals RR Jr, Cortes AL, Parel SM. Fabrication of facial prostheses by applying the osseointegration concept for retention. *J Prosthet Dent* 1989;61:712-6.
- Derhami K, Wolfaardt JF, Faulkner G, Grace M. Assessment of the periosteal device in baseline mobility measurements of craniofacial implants. *Int J Oral Maxillofac Implants* 1995;10:221-9.
- Holgers KM, Thomsen P, Tjellström A, Ericson LE, Bjursten LM. Morphological evaluation of clinical long-term percutaneous titanium implants. *Int J Oral Maxillofac Implants* 1994;9:689-97.
- Tjellström A. Osseointegrated implants for replacement of absent or defective ears. *Clin Plast Surg* 1990;17:355-66.
- Watson RM, Coward TJ, Forman GH. Results of treatment of 20 patients with implant-retained auricular prostheses. *Int J Oral Maxillofac Implants* 1995;10:445-9.
- Nishimura RD, Roumanas E, Moy PK, Sugai T, Freymiller EG. Osseointegrated implants and orbital defects: U.C.L.A. experience. *J Prosthet Dent* 1998;79:304-9.
- Arcuri MR, LaVelle WE, Fyler A, Funk G. Effects of implant anchorage on midface prostheses. *J Prosthet Dent* 1997;78:496-500.
- Wiseman S, Tapia G, Schaaf N, Sullivan M, Loree T. Utilization of a plastic «washer» to prevent auricular prosthesis abutment overgrowth: report of a case and description of a technique. *Int J Oral Maxillofac Implants* 2001;16:880-2.
- Verdonck HW, Poukens J, Overveld HV, Riediger D. Computer-assisted maxillofacial prosthodontics: a new treatment protocol. *Int J Prosthodont* 2003;16:326-8.
- Khamis MM. Clinical and microbiological evaluation of peri-implant tissues of implants retaining auricular prostheses. *Egypt Dent J* 2003;49:595-604.
- Dib LL, de Oliveira JA, Sandoval RL, Nannmark U. Porous surface of extraoral implants: report of two cases rehabilitated with a new Brazilian extraoral implant. *Braz J Oral Sci* 2004;3:633-8.
- Schlegel KA, Schultze-Mosgau S, Eitner S, Wiltfang J, Rupprecht S. Clinical trial of modified ankylos implants for extraoral use in cranio- and maxillofacial surgery. *Int J Oral Maxillofac Implants* 2004;19:716-20.
- Nishimura RD, Roumanas E, Sugai T, Moy PK. Auricular prostheses and osseointegrated implants: UCLA experience. *J Prosthet Dent* 1995;73:553-8.
- Lemon JC, Chambers MS. Locking retentive attachment for an implant-retained auricular prosthesis. *J Prosthet Dent* 2002;87:336-8.
- Lemon JC, Martin JW, Chambers MS, Wesley PJ. Technique for magnet replacement in silicone facial prostheses. *J Prosthet Dent* 1995;73:166-8.
- Gary JJ, Donovan M. Retention designs for bone-anchored facial prostheses. *J Prosthet Dent* 1993;70:329-32.
- Thomas KF. Freestanding magnetic retention for extraoral prosthesis with osseointegrated implants. *J Prosthet Dent* 1995;73:162-5.
- Reisberg DJ, Habakuk SW. Hygiene procedures for implant-retained facial prostheses. *J Prosthet Dent* 1995;74:499-502.
- Beumer J III, Curtis TA, Marunick MT. Maxillofacial rehabilitation: prosthodontic and surgical considerations. St. Louis: Elsevier; 1996. p. 436-44.
- Renouard F, Arnoux JP, Sarment DP. Five-mm-diameter implants without a smooth surface collar: report on 98 consecutive placements. *Int J Oral Maxillofac Implants* 1999;14:101-7.
- Asher ES, Evans JH, Wright RF. Simple method to make a night guard for an extraoral superstructure. *J Prosthet Dent* 2001;86:667.

Corresponding author:

Dr Mohamed Moataz Khamis
20 Amin Fekry Street
El Raml Station
Alexandria
EGYPT
Fax: 203 4865416
E-mail: moataz_khamis@yahoo.com

Copyright © 2008 by the Editorial Council for
The Journal of Prosthetic Dentistry.